



**Renee McCutchan** had a tremendous impact on the swimming community in Morgantown, West Virginia over 33 years. She is one of the most outstanding swimmers in West Virginia University program history. She coached and taught swimming at the high school level, with Special Olympics, and at Stepping Stones. Renee is known to her teammates as a fierce, yet immensely humble, competitor. Everyone who was blessed to know Renee understood that the least special thing about Renee was her swimming.

In July 2020 Renee was diagnosed with a form of melanoma known as acral melanoma, which presents on the soles of feet and palms of hands. When diagnosed and treated early, melanoma prognosis can be very positive. Renee passed away from complications of her melanoma just 13 months after being diagnosed.

## ABOUT MOLLIE'S FUND

As a sophomore in college, Mollie Biggane discovered a mole on her thigh. In the following six months, she underwent surgery, chemotherapy and radiation. **The Mollie Biggane Melanoma Foundation** was created in her memory after her tragic death at the age of twenty. The mission of Mollie's Fund is to increase awareness for melanoma prevention, provide information and services on skin cancer detection, and support melanoma patients through education of the latest treatments.



MOLLIESFUND.ORG

# ACRAL LENTIGINOUS MELANOMA



PREVENT ALM FROM  
ADVANCING WITH  
**EARLY DIAGNOSIS**



# ACRAL LENTIGINOUS MELANOMA

## Warning Signs

- An irregularly shaped growth or spot on the foot or palm of the hand that is changing or has an unusual color
- A raised patch on the sole or palm
- Pain on the sole of the foot when walking
- A streak in the nail that is not due to a bruise


## Also

- ALM may resemble a plantar wart or fungal infection
- Surface may be flat, but grows inward
- Some tumors involve a loss of color or no change in color
- People with family members who develop melanoma including ALM may be more at risk
- Research into specific causes is ongoing


**Acral Lentiginous Melanoma (ALM)** occurs in minimally sun-exposed areas – hands, feet and skin under the nails. It can appear in all skin types but is more common in people with darker skin and Asian people.

## Diagnosis


As with other forms of melanoma, the “**ABCDE**” rule is used to help describe these threatening moles.

**A**symmetry 


---

**B**order  Irregularity


---

**C**olor  Variation. Too many colors in one mole.

---

**D**iameter  >6mm. Often larger than a pencil eraser.

---

**E**volving  Changing – the **most significant**.



If symptoms suggest that cancer may be present, the next step is usually a biopsy. Recommended treatment therapies are dependent on the extent of involvement. Some people may be able to take part in clinical trials, which can offer access to new treatments not widely available.

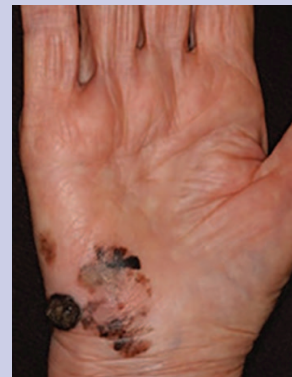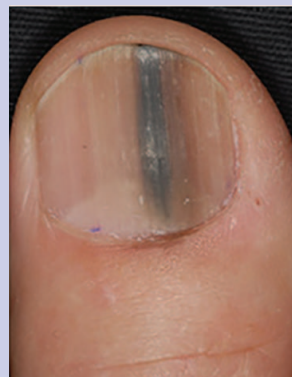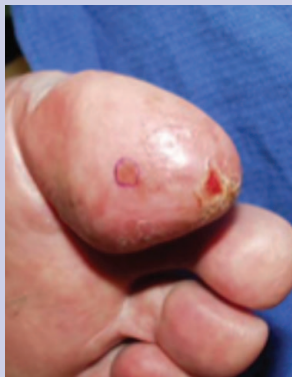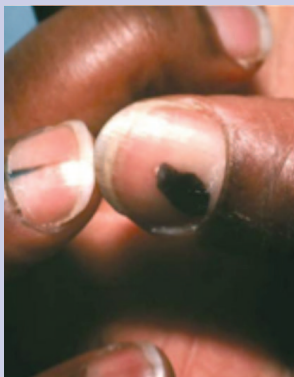


Photo Credit: CDC/Carl Washington, MD, Emory Univ. School of Medicine; Mona Saraiya, MD, MPH

## Prevention

Death rates are higher than other forms of melanoma. This may be because ALM is often misdiagnosed or can go unnoticed. The best way to prevent ALM from advancing is **early diagnosis**. Get an annual skin exam and seek help immediately if an unexplained lesion appears on the foot, hand or nail.